

Histopathological effect of testosterone propionate on male and hydroxyl progesterone caproate on female rain quail, *Coturnix coromandelica*.

P.N. Charde¹, J.S. Ramteke¹, S.B. Zade²

Received: October 2, 2010 | Accepted: December 3, 2010 | Online: July 20, 2011

Abstract

The main aim of this study was to determine the effect of testosterone propionate and hydroxyl progesterone caproate on gonads and some endocrine glands of male and female rain quail. 15 male and 15 female rain quails were treated with testosterone and progesterone daily for 7 and 15 days respectively. The study reveals that after the treatment of testosterone, the spermatogonia were detached and show hypertrophy. The germ cells were enlarged and vacuolated ovary degenerates and thyroid and adrenal show hypertrophy.

Keywords: Testosterone Propionate | Hydroxyl Progesterone Caproate | Sexual Dimorphism | Gonads | Rain Quail.

For Correspondence:

¹Sevadal Mahila Mahavidyalaya, Nagpur (M.S.)

²P.G.T.D. Zoology, Rashtrasant Tukadoji Maharaj Nagpur University, Nagpur (M.S.)

Email: profsbzade@rediffmail.com

Introduction

Quails are almost tailless partridge like bird popularly known as “Batter”, belonging to the class aves and family *Phasianidae*. Batter is a good table bird known for its delicacy since olden days. They are used as food before chicken was domesticated.

Perusal of literature on quail reproduction reveals that, little is known about these aspects in exotic and tropical species. The reason is that more critical experiments have not been successfully undertaken in Indian quail species. Studies on these species are confined mainly to the changes in the reproductive organs and rarely endocrine glands during different phases of reproductive cycle. No experimental studies have been made in these species endocrine glands in reproduction. Fundamental knowledge of reproductive process and the endocrine mechanism that control process is therefore, invisible for profitable management and production of these birds in large scale. The paucity of information on reproductive endocrinology of Indian quail motivated us to undertake this investigation.

The present study was undertaken on rain quail, *Coturnix coromandelica*. This bird was selected as it offers the advantages of endocrinological works. The aim and objective of this investigation is to study the histopathological effect of testosterone propionate and hydroxy progesterone caproate on gonads and other endocrine glands

and to investigate the mechanism of action of this steroids in both sexes of rain quail.

In the present study testosterone propionate and hydroxyl progesterone caproate were obtained from German Remedies Limited, Bombay under trademark of Schering AG, West-Germany.

MATERIAL AND METHODS

The Indian rain quail *C. coromandelica* has been selected for present investigation. Adult quail are sexually dimorphic. Reproductive behaviour is sexually differentiated in quail. The adult rain quail is about 6½ to 7 inches in size (without tail) and body weight is 85 to 90 gms. Temperature, light, floor space, humidity and feed are most important factors for good housing and maintenance of quails. The maximum daily amount of feed given was equivalent to 20 to 25% of body weight. To identify individual quails from each groups, they were marked with numbered aluminium strips using bands.

The rain quail utilized in this study were collected from various places in Nagpur district and Amravati district of Maharashtra State. The birds were trap over a period of four months during October to January and consisted of 60 adult males and 40 adult females weighing 70 to 90 gms. Before commencement of the experiments all birds were acclimatized in laboratory for at least 2 to 3 weeks.

The males are divided into four groups of 15 animals each. The ground II and IV are given intramuscular injection of testosterone propionate 0.15 mg/kg/day for 7 and 15 consecutive days respectively. The I and III group receive equivalent volume of physiological saline for the same period. For another experiment 40 female birds were divided into four groups of 10 birds each. The

group II and IV were given intramuscular injection of hydroxy progesterone caproate 0.15 mg/kg/day consecutive for 7 and 15 days respectively. The I group and II were used as a control and treated with equivalent volume of physiological saline for the same period. Birds of experimental and control groups were weighed before and at the end of the experiments and maintained under same husbandry condition. At the end of each experimental animals were sacrificed. For histopathological studies reproductive organs and endocrine glands were dissected, weighed and fixed in various fixatives. All endocrine glands were fixed in formal sublimate for 24 Hrs. and other tissue were fixed in Bouin's fluid. The tissue were dehydrated in various grades of alcohol cleared in xylene and after embedded in paraffin blocks were prepared. Paraffin sections were cut at 5 to 6 µm thickness. Sections were stained with haematoxyline and eosin.

HISTOMORPHOLOGY

Testis – The testis consists of compact convoluted seminiferous tubules which are lined by single or double layer of germinal cells. The tubules are composed of primary spermatogonia, secondary spermatogonia and sertoli cells. Further stages of spermatogenesis such as spermatocytes, spermatids and spermatozoa are not observed. Similarly, the sertoli cells are inconspicuous and regressed. Since, the control males are sacrificed in the month of January which is sexually inactive period in rain quails, the testis have showed regression. In the interfollicular region blood capillaries, connective tissue and regressed Leydig's cells are present.

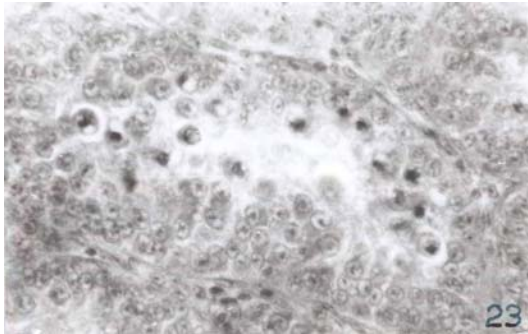
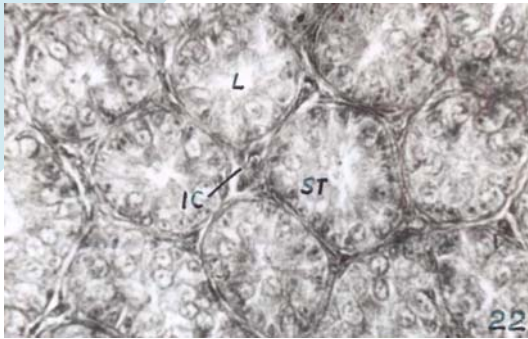


Figure 1: Photomicrograph of control testis showing convoluted seminiferous tubules with germ cells, sertoli cells and interstitial cells.

Ovary:

In the rain quail single ovary and oviduct is present which is situated on the left side of the cephalic end of kidneys and attached the body wall by ligament. In rain quail, the ovary contains several primary follicles and blood haemorrhage. Developing follicles are composed of germinal vesicle granulose cells, theca interna and theca externa. Some degree of atresia is observed at primary follicular stage. Rarely degeneration is visible in large follicles.

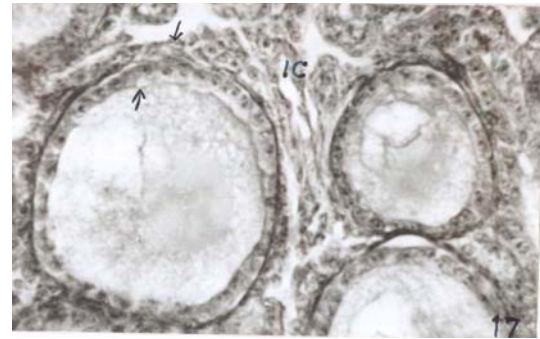
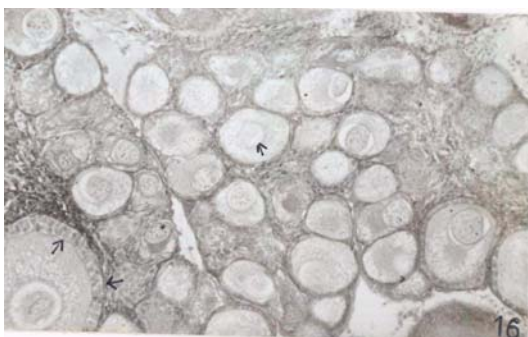


Figure 2: Photomicrograph of control ovary showing primary follicles and germinal follicles with theca externa, theca interna and interstitial cells.

Adrenal gland of rain quail is paired, triangular in shape and yellow or orange in colour. It locates anterior and medial to the cephalic lobe of kidney and posterior to the lungs. It is surrounded by thick capsule which is made up of connective tissue.

Pineal gland is present on the dorsal side of the brain in triangular space between cerebellum and cerebral hemisphere. Pineal grain in rain quail is creamisa brown, club-shaped conical structure. Pineal gland is composed of lobules and each lobule consists of follicles which are separated by intralobular septa.

Thyroid gland of the male and female rain quail is composed of two separate lobes which are reddish in colour, situated on either side of the trachea in between jugular and carotid blood vessels. The normal thyroid gland is encapsulated and composed of well organized compact follicles.

Parathyroid gland in the rain quail is paired, well vascularised and closely attached to the posterior part of the thyroid gland.

RESULTS AND DISCUSSION

Pineal:

7 days after treatment: No significant changes were observed in the vasculature of pineal gland. Lumen of the follicle was

slightly obliterated. Type-I i.e. polygonal cells shows regression whereas Type-II i.e. tall cells shows hypertrophy and degranulation.

15 days after treatment: Showed more pronounced hypertrophy of Type-II i.e. tall columnar cells as compared to 7 days of testosterone propionate. The cell debris in lumen was evident. Type-I i.e. polygonal cells showed more regression.

Thyroids:

7 days after treatment: Testosterone propionate treatment resulted in hypertrophy of the follicular epithelial cells and thickness of follicular wall. It induced hypertrophy and hyperplasia in small follicles. Large follicles showed little regressive effect.

15 days after treatment: Induced changes in thyroid follicles. Diameter of follicles were increased. The gland contained several empty follicles. The colloid contained few vacuoles at the peripheral region. The reduction in the amount of colloid was more evident.

Parathyroid:

7 days after treatment: Testosterone propionate treatment induced hypertrophy and vacuolization in the cells of parathyroid cells of parathyroid gland. Small circular vacuoles appeared adjacent to the nucleus.

15 days after treatment: The above mentioned effect of testosterone propionate were same, rather more pronounced were same, rather more pronounced in the fifteen days treated birds.

Adrenal:

7 days after treatment: No significant changes were found in the vasculature of the gland. No changes were evident in Type II cells while Type I cells showed slight hypertrophy and degradation.

15 days after treatment: More significant changes were seen in the internal cells. The internal cells shows hypertrophy and were degranulated and vacuolated. No significant changes were observed in Type II and showed little hypertrophy as compared to control.

Testis:

7 days after treatment:

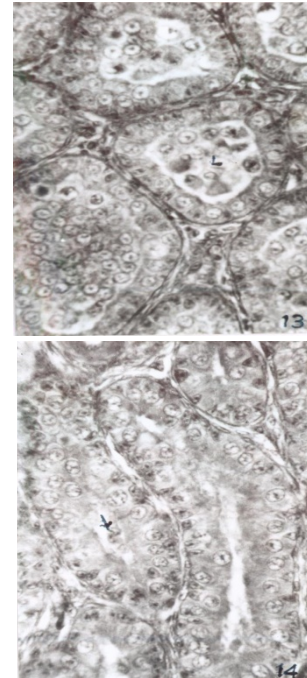


Figure 3: Photomicrograph of testis 7 days treatment of testosterone propionate showing detached spermatogonia in the lumen.

The germinal epithelium was not affected after treatment of testosterone propionate. Debris formation in the lumen of the seminiferous tubules was seen. Regressive changes were observed in peripheral seminiferous tubules. Primary spermatogonia and secondary spermatogonia were detached and seen accumulated in the lumen of seminiferous tubules. In some tubules lumen disappeared because of hypertrophy of germ cells. No changes were observed in the vasculature of gland.

15 days treatment:

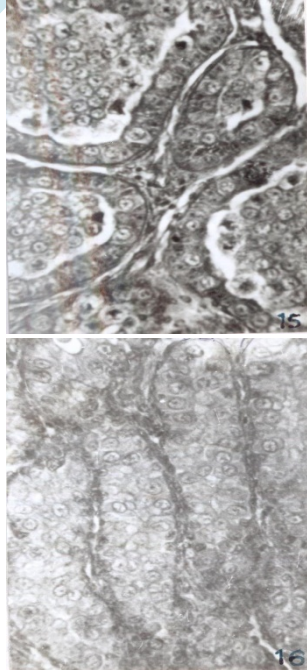


Figure 4: Photomicrograph of testis 15 days treatment of testosterone propionate showing completely obliterated lumen, hypertrophy of Sertoli cells and degenerative effect on Leydig's cells (Interstitial cells)

In most of the tubules germ cells detached and accumulated as debris in the lumen. Germ cells were enlarged and vacuolated. Lumen of seminiferous tubules disappear enlarged size of the primary spermatogonia and secondary spermatogonia showed hypertrophy. Sertoli cells were degenerated while Sertoli cells showed hypertrophy. Blood vessels became dilated.

Ovary

The atretic primary follicles and formation of space between the haemorrhage and ovarian stroma changes. Haemorrhage becomes more viscous. The large follicles show regressive changes.

7 days after treatment:

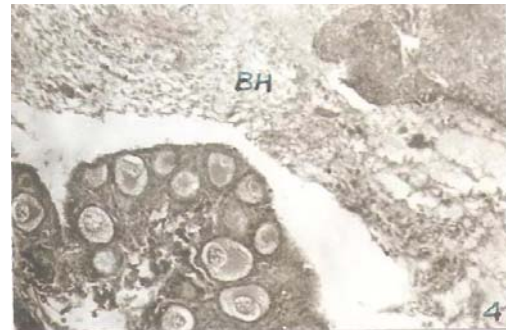


Figure 5: Photomicrograph of Ovary 7 days treatment of hydroxyl progesterone caproate showing primary follicles and formation of space between ovarian stroma and blood haemorrhage

15 days after treatment:

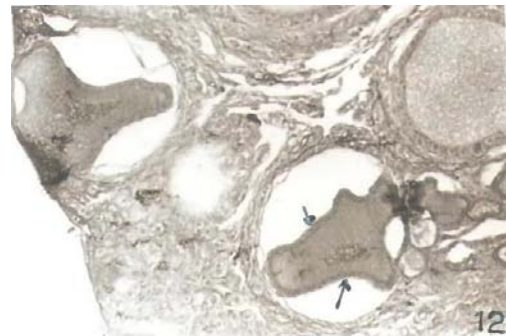


Figure 6: Photomicrograph of Ovary 15 days treatment of hydroxyl progesterone caproate showing greatly regressed germinal vesicle, degenerating large follicles and disturbed interstitial cells.

The space between blood haemorrhage and ovarian stroma is more pronounced. Follicular cytoplasm and germinal vesicle show regressive changes. There was no significant effect on the theca interna and theca externa, but these two layers started to separate from each other in large follicles. In stroma interstitial cells show more degenerative changes.

CONCLUSION:

From the present study it has been concluded that the doses of testosterone propionate stimulates the spermatogenesis in male rain quail. Similarly the treatment of hydroxyl progesterone caproate in female stimulates the secretion of FSH of pituitary and development of ovarian follicles.

References

- Arneja, D.V., George, G.C., Mehta, S.N. Dixit, V.P. and Razdan, M. N. (1984). Plasma testosterone concentration in relation of thyroid status in Japanese quail. *Indian J. Poultry Science*, 19, 207-209.
- Arneja, D.V. and Singal, S. P.(1986). Testicular development in relation to thyroid status in turkeys Toms Malaegris gallopavo. *Indian Journal of Animal reproduction*. 20, 73-75.
- Balsubramanium, K. S. and Subramanium. R. S.(1979). In abstract, Third All India Symposium on Comparative Endocrinology, Utkal University, Bhuwaneshwar.
- Cardinali, D. P. Cuello, A. E., Tramezzini, J. H. and Rosner, J. M. (1971). Effects of pinealectomy on the testicular functions of the adult male ducks. *Endocrinology*, 89, 1082-1093.
- Chand, D and Arneja, D.V. (1986). Influence of thyroid status of plasma cholesterol of Turkeys Toms Malaegris gallopavo. *Life Science Adv*.
- Dawson, A., Goldsmith, A. R. Nicholls, T. J. and Follett, B. K. (1986). Seasonal changes in testicular size and in plasma follicle stimulating hormone and prolactin concentration in thyroidectomized male and thyroidectomized castrated starling *Sturnus vulgaris*. *Gen.Comp.Endo*.63, 38-44.
- Doi, O., Takai, T., Nakamura, T., and Tanabe, Y. (1980). Changes in the pituitary and plasma LH, plasma and follicular progesterone and estradiol and plasma testosterone concentration during the ovulatory cycle of the quail *Coturnix coturnix japonica*. *Gen.Comp.Endo*. 41, 156-163.
- Furuya, T and Ishii, S.(1976). Effects of follicle stimulating hormones and leutinizing hormone on the incorporation of ³²P into the testis of the immature.J.quail. *Gen.Comp.Endo*. 29. 556-559.
- Follet, B. K. and Nicholls, T. J.(1985). Influences of thyroidectomy and thyroxine replacement on photoperiodically controlled reproduction in quail. *J.Endocrinology*. 107,21-21.
- Haldar, C. and Ghosh, M.(1990). Annual pineal and testicular cycle in the Indian jungle bush quail, *Perdica asiatica* with reference to the effect of pinealectomy. *Gen.Comp.Endocrinology*, 77, 150-157.
- Howrath, B. Jr. and Marks, H. L.(1972). The effect of thyroidectomy on testicular size and on the photoperiodically controlled reproduction in quail. *J.Endocrinology*. 107, 211-221.
- Hammond, R. W., Burke, W.H. and Hertelendy ,F.(1981a). Influence of follicular maturation on progesterone release in chicken granulose cells in response to Turkey and ovine gonadotrophins. *Biol.Reprod*.24, 1048-1055.
- Hervey, E. and Hervey, G. R. (1967). The effects of progesterone on body weight and composition in the rat. *Journal of Endocrinology*. 37: 361-384.
- Marrone, B. L. and Hertelendy, F.(1985). Decrease androsterone production with increased follicular maturation in the thecacells from domestic *Gallus domesticus*. *J.Reprod.and Fertility*. 7, 543-550.

- Patel, M. N. (1984).Pineal in relation to breeding and carbohydrates metabolism. Histophysiological studies in domestic and wildpigeons, *Columbia livia*, Ph.D.Thesis, University of Baroda,
- Ramchandran,A.V., Patel,C.D., Asnani,M.V. and Shash,R.V.(1987). Seasonal histomorphological changes in the gonads on the normal and pinealectomized feral blue rock pigeons, *Columba livia*, *Monitore Zool., et al.*, 21,2.
- Sayler, A. and Wolfson, A. (1968).Influence of the pineal gland on gonadal maturation in the J.quail. *Endocrinology*, 83, 1237-1246.
- Snapir, N., Robiosson, B. Holfman, Y and Berman, A. (1982). Adenohypophyseal cytology of chemically thyrosectomized cockrels. *Poultry Sci.* 61, 1720-1728.
- Sturkie, P. E. (1976). Avian Physiology, third Edition, Springer Verlag, New York,Heidenberg,Berlin,PP.1-388.
- Shrikhande, D. J.(1978).An experimental analysis of certain pituitary-adrenal gonadal relationship in Indian fruit bat *Rousettus leschenaulh*.Ph.D.Thesis,Nagpur University, Nagpur
- Turek, F. W., Dasjardin, C. and Menaker, M. (1976). Antigonal and pregonal effects of testosterone in male house sparrows. *Gen.Comp.Endo.* 28, 395-402.
- Wieselthier. A. S. and Van-Tienhoven. A. (1972). The effect of thyroectomy on testicular size and on the photorefractory period in the Starling *Sturnus vulgaris*. *J.Exp.Zool.*179, 331-339.

